EPOS™
Electronic Presentation Online System

European Society of Radiology

Doppler ultrasound in Budd-Chiari syndrome.

Poster No.: C-1319

Congress: ECR 2014

Type: Educational Exhibit

Authors: C. Oliveira[1], R. Amaral[2], M. Magalhaes[1], C. Xavier[1], E. Pinto[1], F. Caseiro Alves[1]; [1]Coimbra/PT, [2]Ponta Delgada/PT

Keywords: Education and training, Diagnostic procedure, Ultrasound-Spectral Doppler, Ultrasound-Power Doppler, Ultrasound-Colour Doppler, Liver

DOI: 10.1594/ecr2014/C-1319

Any information contained in this pdf file is automatically generated from digital material submitted to EPOS by third parties in the form of scientific presentations. References to any names, marks, products, or services of third parties or hypertext links to third-party sites or information are provided solely as a convenience to you and do not in any way constitute or imply ECR's endorsement, sponsorship or recommendation of the third party, information, product or service. ECR is not responsible for the content of these pages and does not make any representations regarding the content or accuracy of material in this file.
As per copyright regulations, any unauthorised use of the material or parts thereof as well as commercial reproduction or multiple distribution by any traditional or electronically based reproduction/publication method ist strictly prohibited.
You agree to defend, indemnify, and hold ECR harmless from and against any and all claims, damages, costs, and expenses, including attorneys' fees, arising from or related to your use of these pages.
Please note: Links to movies, ppt slideshows and any other multimedia files are not available in the pdf version of presentations.
www.myESR.org

Learning objectives

To review Budd-Chiari Syndrome physiopathology.

To describe the Doppler ultrasound imaging findings in Budd-Chiari Syndrome.

Background

Hepatic veins

Hepatic Doppler ultrasound evaluates three major vascular structures: arterial, venous and portal systems. Usually the normal hepatic venous system consists of three major hepatic veins: right, medium and left hepatic vein. They enter the retrohepatic inferior vena cava just before it traverses the diaphragm, approximately 2cm caudad to the right atrium and eustachian valve. The middle hepatic vein and the left hepatic vein may share a common trunk (65-85% of patients). Besides the three major hepatic veins, additional small accessory hepatic veins from the pericaval liver segments may drain directly into the inferior vena cava caudad to its junction with the major veins. These accessory veins are usually associated with the right lobe or caudate lobe and may occasionally be up to 1 cm in diameter (Fig. 1 on page 5).

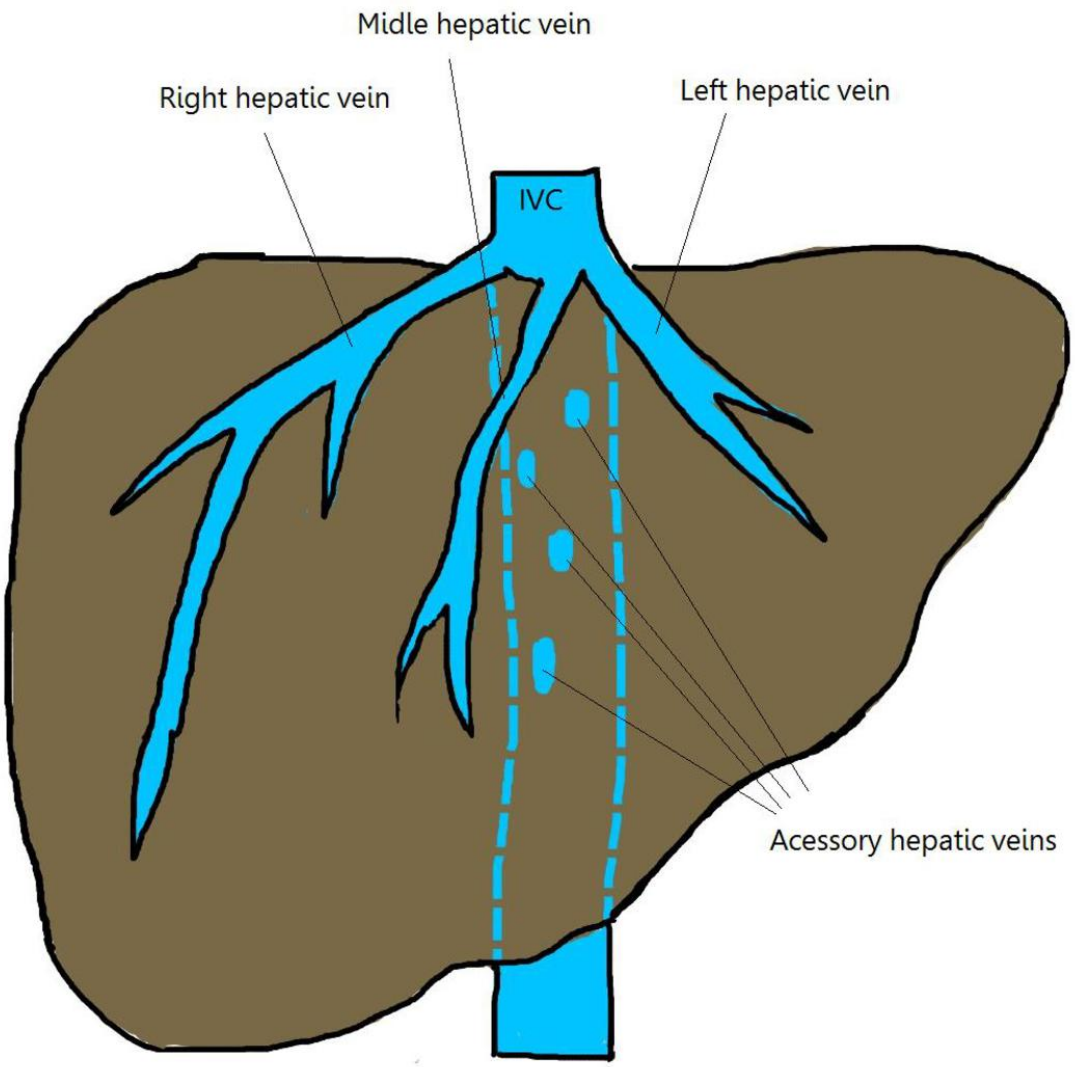

Fig. 1: Schematic figure showing the hepatic venous drainage (IVC - inferior vena cava).
References: Radiologia, Hospital Geral, Centro Hospitalar e Universitário de Coimbra - Coimbra/PT

Budd-Chiari Syndrome pathophysiology

The Budd-Chiari syndrome is a clinical phenomenon caused by a hepatic venous outflow obstruction (Fig. 2 on page 6), which can be located anywhere above the level of the hepatic venules and results in characteristic triad: congestive hepatomegaly, abdominal pain, and ascites. Budd-Chiari Syndrome is also a rare but important cause of portal hypertension.

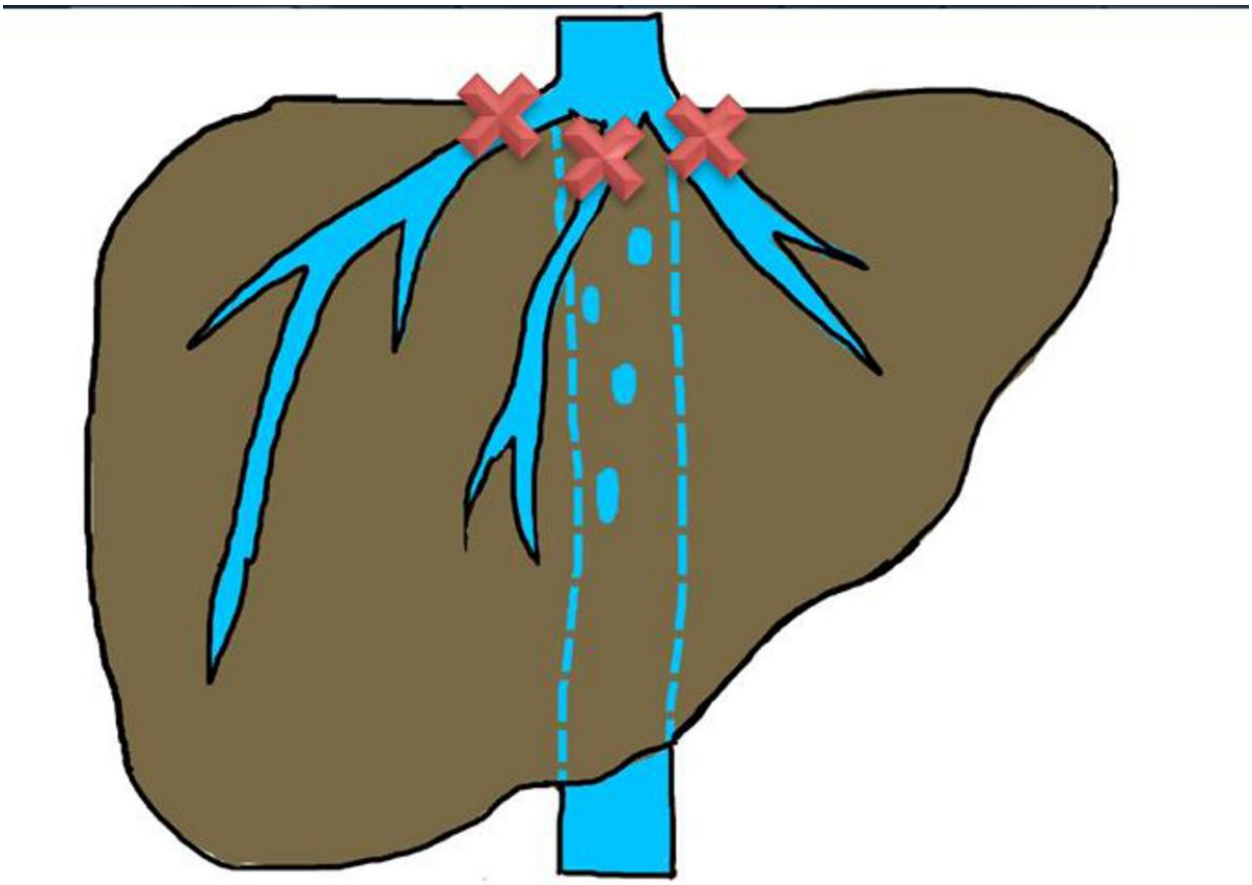

Fig. 2: Schematic figure showing the Budd-Chiari Syndrome pathophysiology: venous obstruction flow.
References: Radiologia, Hospital Geral, Centro Hospitalar e Universitário de Coimbra - Coimbra/PT

Primary type is caused by thrombosis or intrinsic luminal web, and secondary type by tumor invasion or extraluminal compression. In Western countries, thrombosis is by far the leading cause of obstruction of the major hepatic veins. as result of a prothrombotic disorder (> 75% of patients), whereas membranous obstruction of the inferior vena cava is the cause of most cases in Asia. Young women are predominantly affected. Symptomatic hepatic vein thrombosis is almost always due to an underlying myeloproliferative disorder, hypercoagulable state, or other predisposing factors such as the use of oral contraceptives. Hepatic vein thrombosis may also be due to infection, tumor invasion, or sequelae of trauma.An increasingly important cause of hepatic venous outflow obstruction is venous anastomotic stricture in patients who have undergone liver transplantation. Torsion of the right liver graft and hypertrophy of the graft with compression of the inferior vena cava are other reported causes of venous outflow obstruction in this patient population.

The clinical correlation depends on both the extent of the obstructive process and how quickly it develops. Budd-Chiari Syndrome may be fulminant with rapidly progressive liver failure (uncommon) or acute or subacute, with abdominal pain, ascites, hepatomegaly, and renal failure developing over a week or two. Chronic form, with ascites developing over 2 months or more is more common. In subacute and chronic Budd-Chiari Syndrome, complications of portal hypertension determine prognosis and are fatal in more than 50% of patients within 2 years.

Treatment includes anticoagulation therapy, management of portal hypertension complications, liver decompression (transjugular intrahepatic portosystemic shunt [TIPS] or surgical portosystemic shunt), and liver transplantation. Patients surviving for 2 years after diagnosis have a good prognosis (Table 1 on page 7).

Budd-Chiari Syndrome	
Pathophisiology	Hepatic venous outflow obstruction
Etiology	Primary type - Thrombosis (myeloproliferative disorder, hypercoagulable state, oral contraceptives, infection, trauma., transplant complication) - Luminal web Secondary type - Tumor invasion - Extraluminal compression
Clinical signs	Hepatomegaly, abdominal pain, and ascites
Treatment	Anticoagulation Management of portal hypertension complications Liver decompression (transjugular intrahepatic or surgical portosystemic shunt) Liver transplantation
Prognosis	Good, if surviving for to 2 years after diagnosis

Table 1: Budd-Chiari Syndrome characteristics.
References: Radiologia, Hospital Geral, Centro Hospitalar e Universitário de Coimbra - Coimbra/PT

Images for this section:

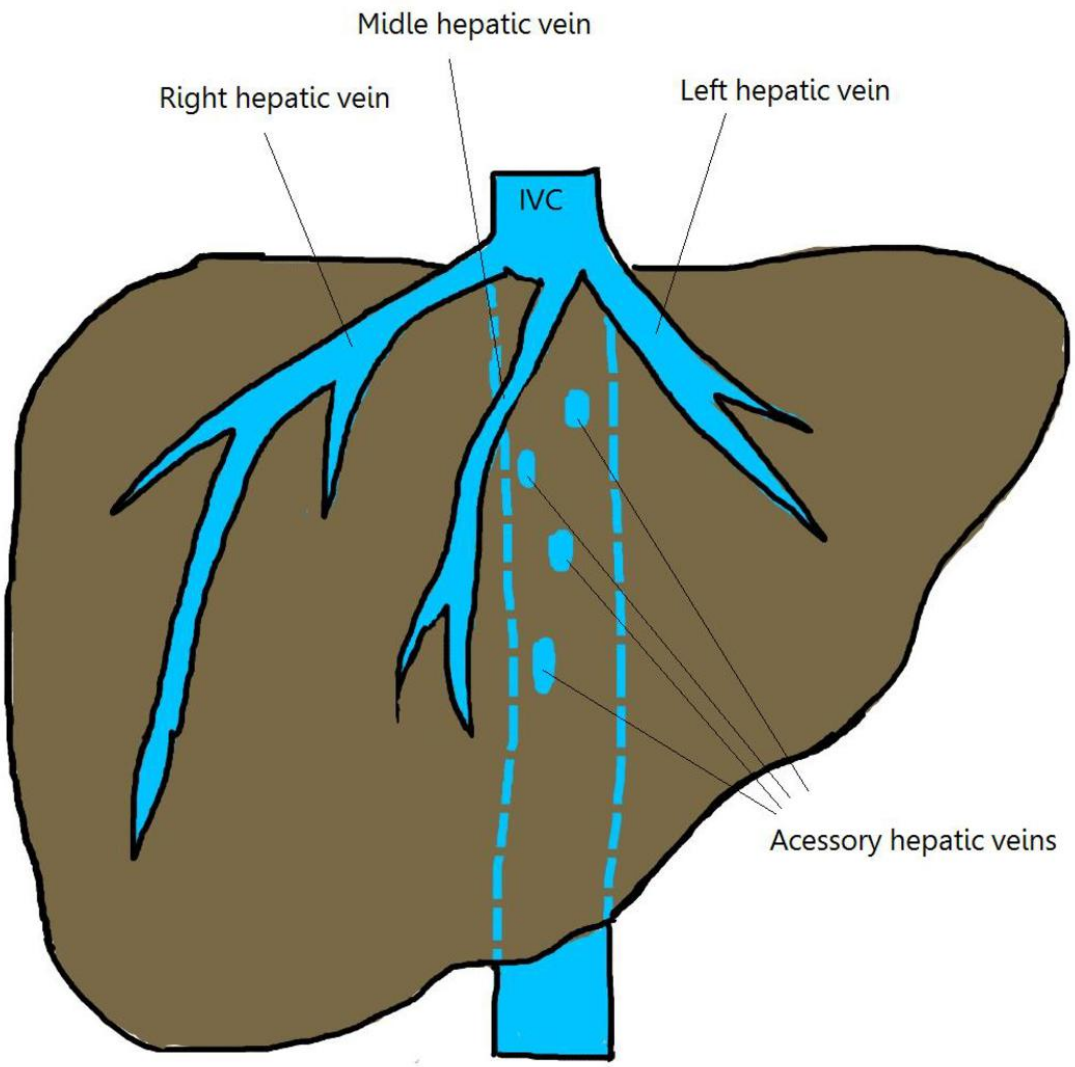

Fig. 1: Schematic figure showing the hepatic venous drainage (IVC - inferior vena cava).

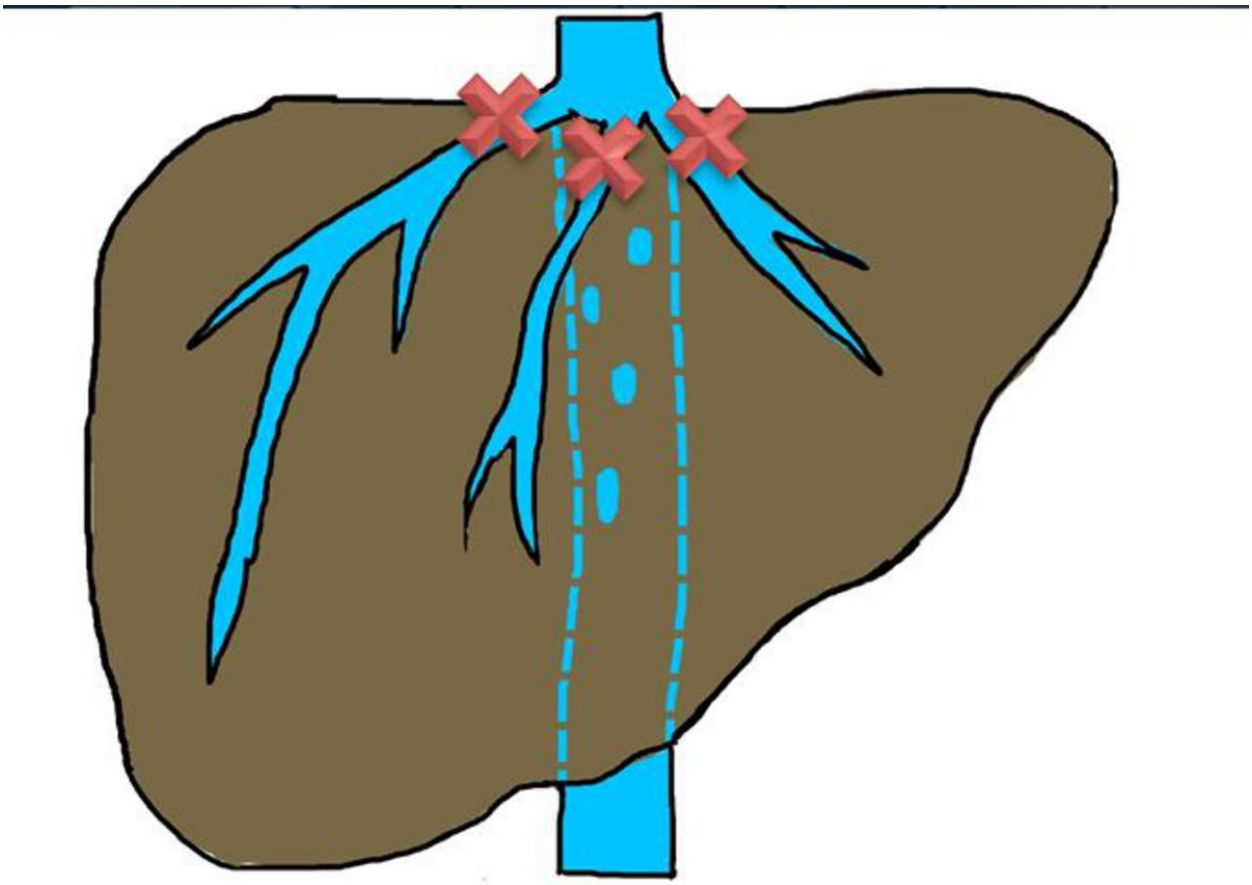

Fig. 2: Schematic figure showing the Budd-Chiari Syndrome pathophysiology: venous obstruction flow.

Budd-Chiari Syndrome	
Pathophisiology	Hepatic venous outflow obstruction
Etiology	Primary type - Thrombosis (myeloproliferative disorder, hypercoagulable state, oral contraceptives, infection, trauma., transplant complication) - Luminal web Secondary type - Tumor invasion - Extraluminal compression
Clinical signs	Hepatomegaly, abdominal pain, and ascites
Treatment	Anticoagulation Management of portal hypertension complications Liver decompression (transjugular intrahepatic or surgical portosystemic shunt) Liver transplantation
Prognosis	Good, if surviving for to 2 years after diagnosis

Table 1: Budd-Chiari Syndrome characteristics.

Findings and procedure details

Normal hepatic veins ultrasound features

In gray scale mode, the walls of the hepatic vein are echogenic only with perpendicular beam incidence (Fig. 3 on page 19)(unlike the portal veins whose walls are echogenic). This is due to differences in the orientation of connective tissue fibers in the vessel walls, which are parallel and tightly packed in the hepatic veins but only loosely arrayed in a variety of directions along the portal veins.

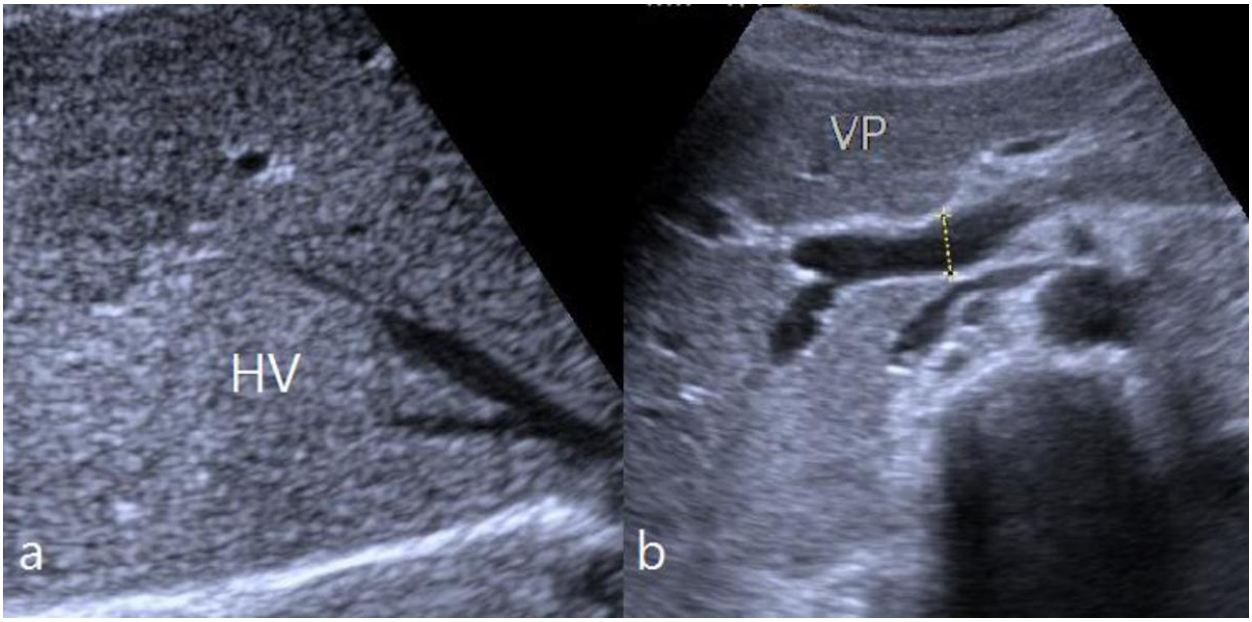

Fig. 3: Ultrasound images of normal hepatic veins (a) and portal vein (b) in gray scale (HV - hepatic veins; VP - portal vein).
References: Radiologia, Hospital Geral, Centro Hospitalar e Universitário de Coimbra - Coimbra/PT

The hepatic veins reflect the pressure variations within the right atrium during the cardiac cycle. In Doppler ultrasound evaluation, hepatic veins normally present a triphasic waveform pattern with respiratory modulation (Fig. 4 on page 19).

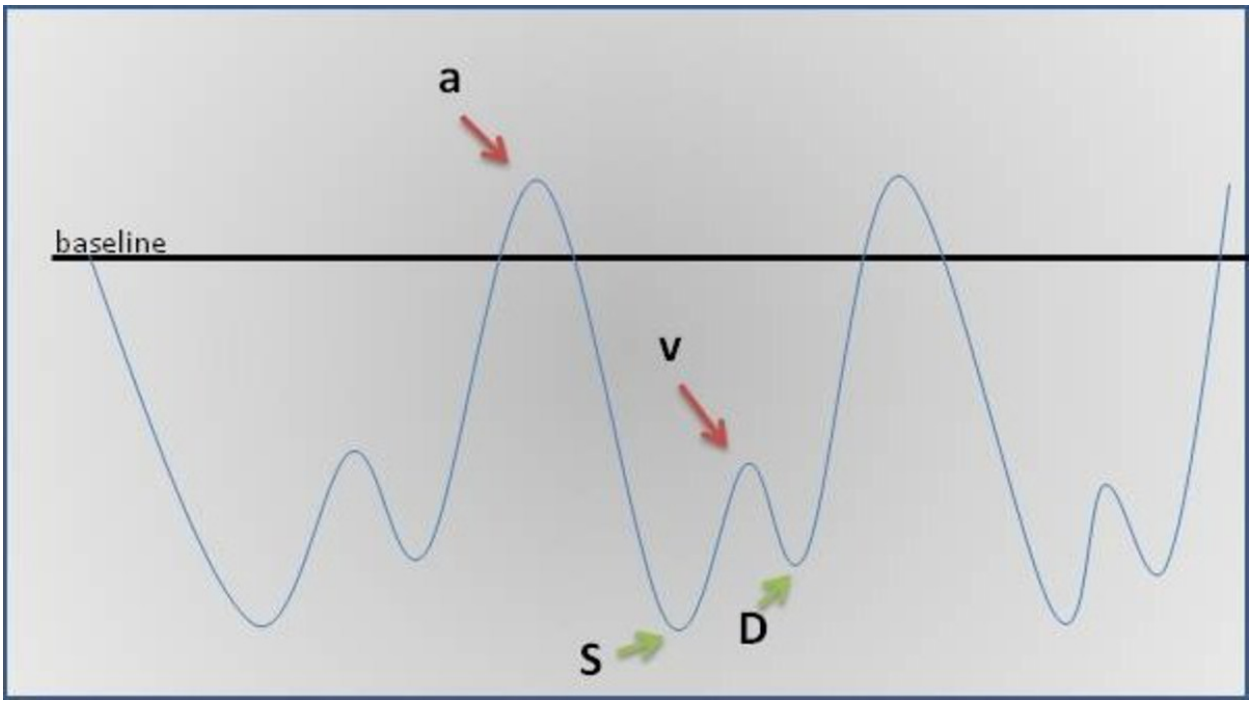

Fig. 4: Schematic figure showing the normal triphasic trace in Dopller evaluation of the hepatic veins.
References: Radiologia, Hospital Geral, Centro Hospitalar e Universitário de Coimbra - Coimbra/PT
There is a low-velocity phase of retrograde flow during right atrial contraction (*a* wave), followed by two phases of hepatofugal flow: the first during right ventricular systole, and the second during right ventricular diastole. Between these two phases, preceding the opening of the tricuspid valve, the atrial pressure rises briefly (the *v* wave), which may produce a short second period of hepatic venous flow reversal, even in healthy patients. *V* wave flow reversal is almost always smaller than the *a* wave flow reversal (Fig. 5 on page 20).

To minimize the effect of the adjacent inferior vena cava, Doppler sonography sample volume should be placed 3-6 cm from the vessel outlet. Suspended respiration but not to deeply inhalation or exhalation is preferred because these maneuvers alter venous pressures and consequently the hepatic venous waveform. Also, because hepatic blood flow increases in the postprandial state, patients should be examined when fasting.

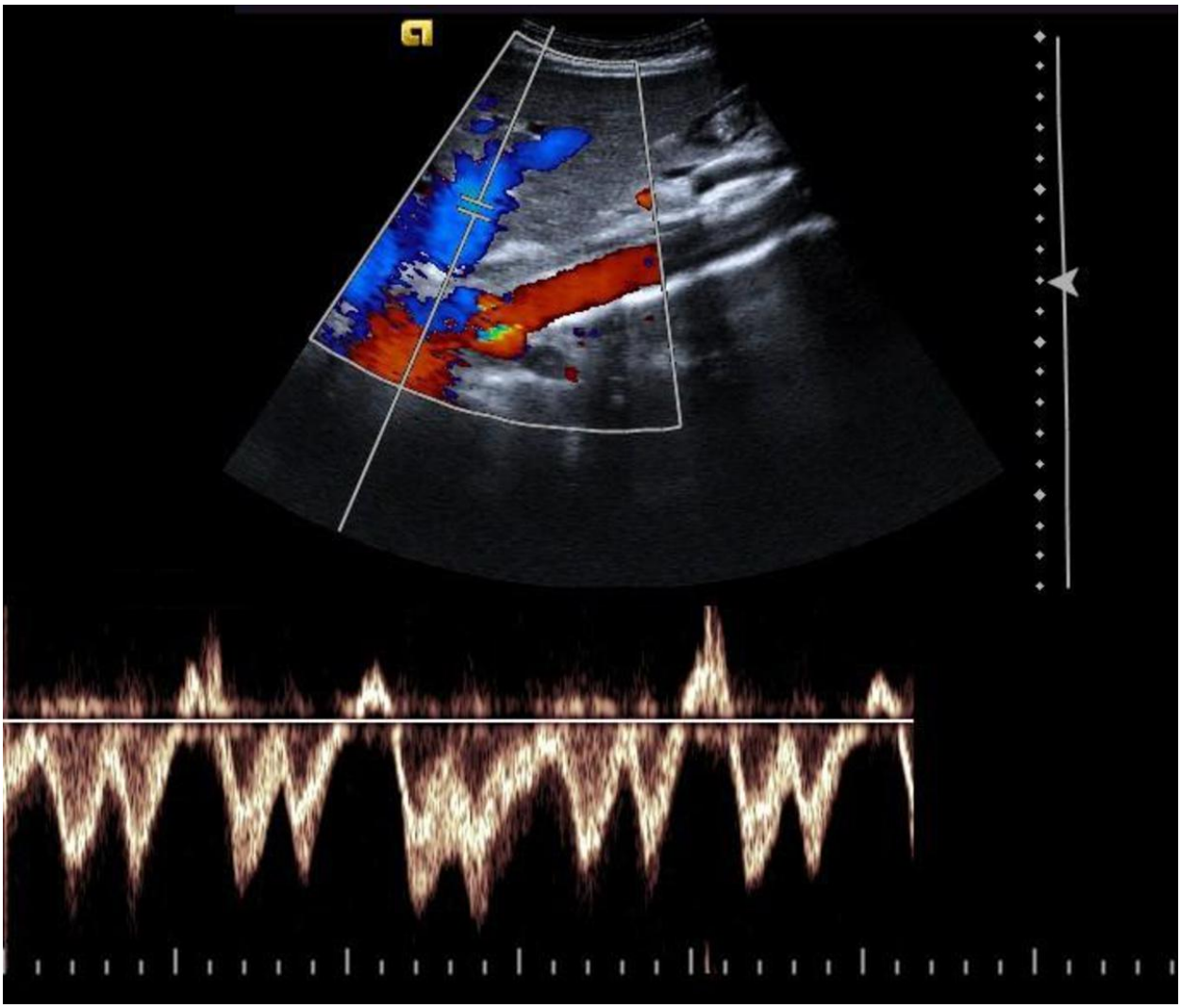

Fig. 5: Normal color and spectral evaluation of an hepatic vein.
References: Radiologia, Hospital Geral, Centro Hospitalar e Universitário de Coimbra - Coimbra/PT

Budd-Chiari Syndrome ultrasound features

Budd-Chiari syndrome imaging features may be categorized in three types of signs:

- *More specific signs*, that include hepatic vein involvement (e.g., non visualization, fibrous cord, thrombosis, and stenosis);
- *Suggestive signs* such as evidence of intrahepatic collateral circulation (e.g., spiderweb collaterals, subcapsular vessels, arcuate vessels to the inferior vena cava, collaterals between portal and venous hepatic systems) and a caudate vein enlargement;
- *Less specific signs*, that are found in other conditions such as benign regenerative nodules, caudate lobe hypertrophia, nonhomogeneous

parenchymal structure, portal thrombosis, recanalized umbilical vein, and ascites.

Hepatic veins

Findings that suggest hepatic vein involvement are: nonvisualization of the vein on Doppler color sonography; the presence of a fibrous cord replacing the vein or a thrombus filling the lumen and vein stenosis.

A thrombotic or a stenotic vein with proximal dilatation and reversed flow in one or more of the hepatic veins are specific signs of Budd-Chiari Syndrome.

Absence of phasicity (monophasic flow) (Fig. 6 on page 24), tortuosity or non visualization of the hepatic veins are common, but no specific signs, as they can also be found in patients with cirrhosis or advanced right heart failure. Many causes of hepatomegaly result in sufficient compression of the hepatic veins to render them nonvisible to real-time sonography, although they are patent.

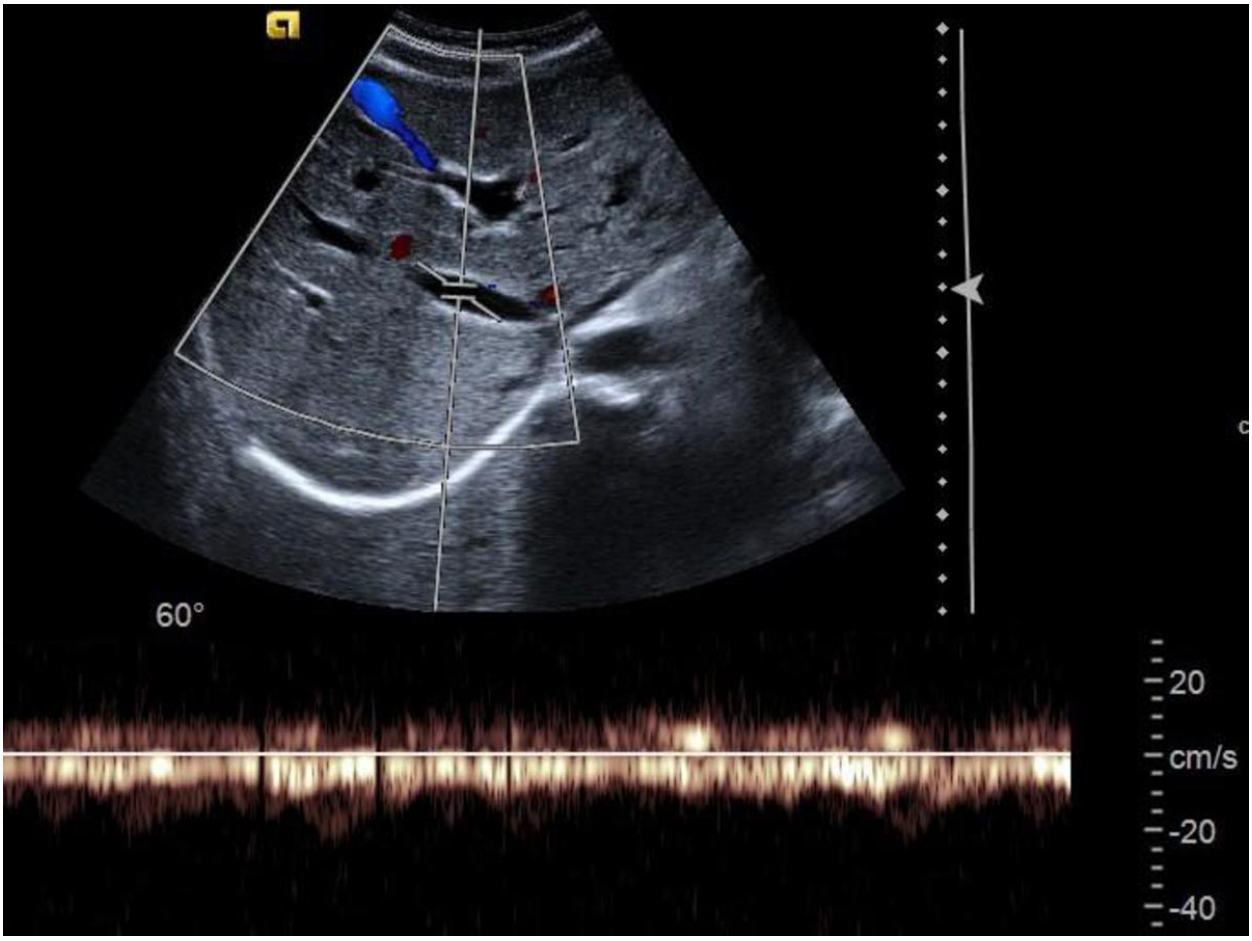

Fig. 6: Abnormal spectral Doppler of an hepatic vein - monophasic trace.
References: Radiologia, Hospital Geral, Centro Hospitalar e Universitário de Coimbra - Coimbra/PT

Gray-scale sonography may show low-level echogenic material within the normally sonolucent lumen of the hepatic vein (Fig. 7 on page 21). However, even if the hepatic veins appear patent on gray-scale and color Doppler sonography, spectral tracings should be obtained.

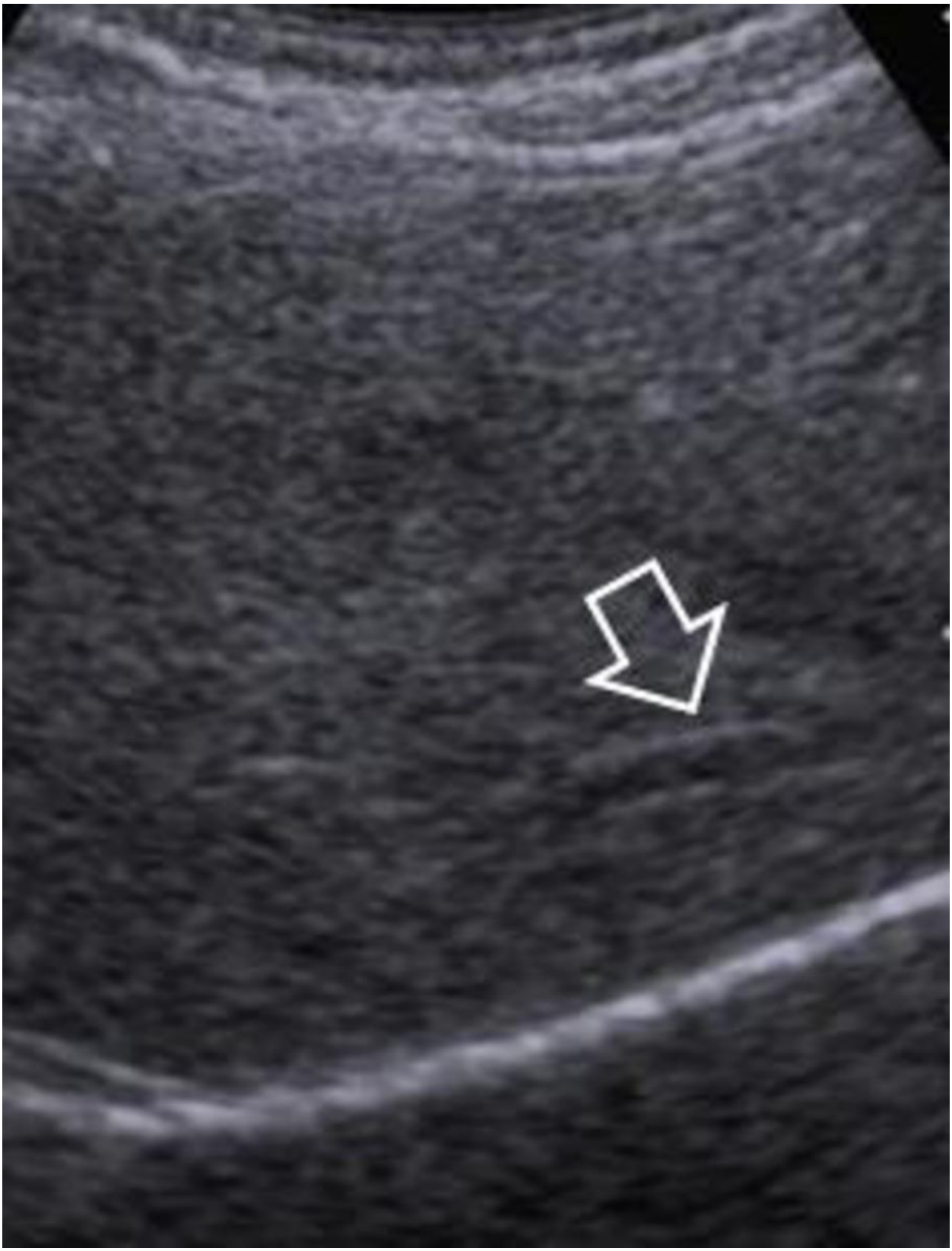

Fig. 7: Gray scale ultrasound showing echogenic material within the lumen of the hepatic vein (white arrow).

As cardiac pulsations are prominently transmitted into the left lobe of the liver diagnosis of middle and left hepatic the ability to adequately evaluate the hepatic vasculature with duplex Doppler in Budd-Chiari Syndrome may be limited.

Color Doppler imaging, however, offers considerably more diagnostic information. Color-flow imaging gives a real-time overview of all vascular events within the plane of section. In this regard, the middle and left hepatic veins are situated almost parallel to the Doppler beam when scanning is done in the transverse plane at the level of the xyphoid. This angle allows optimum reception of their Doppler signals. Conversely, the right hepatic vein is imaged best from a lateral intercostal approach, again optimizing the Doppler angle.

Occlusion of a single vein is usually clinically silent, but two or three main hepatic veins can be occluded without significant symptoms. This fact may be explained by a step-by-step occlusion of one followed by two or more veins with simultaneous development of venous collaterals.

The inferior vena cava is often involved, and can show loss of phasic oscillation or even a reversed flow.

Collateral Circulation

To decompress liver parenchyma, intrahepatic blood has to find a pathway to exit the liver. These pathways include the intrahepatic venousvenous and portocaval and extrahepatic collaterals.

- ***Intrahepatic venovenous collaterals -***they provide alternative pathways for venous return to the right heart when the inferior vena cava or the hepatic veins are obstructed. The newly formed vessels can be spiderweb collaterals, large venovenous collaterals draining to the inferior vena cava and subcapsular veins that may be identified on the surface of the liver. Alternatively, blood may be shunted away from an obstructed hepatic vein and toward a patent one, producing a pattern of bicolored hepatic veins (two adjoining hepatic veins with flow in opposite directions on color Doppler sonography) (Fig. 8 on page 23).

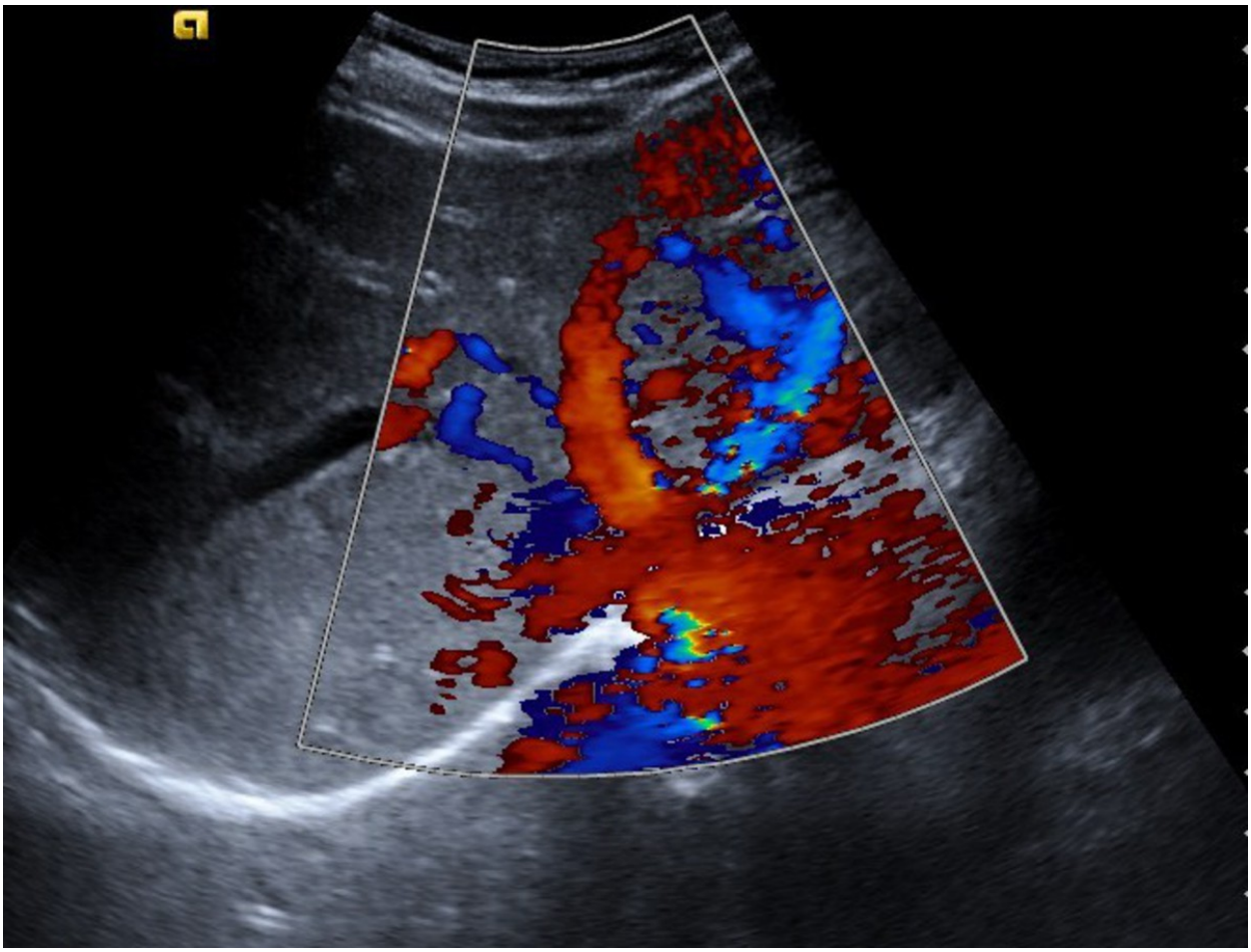

Fig. 8: Color Dopler ultrasound showing a pattern of bicolored hepatic veins (two adjoining hepatic veins with flow in opposite directions on color Doppler sonography). ***References:*** Radiologia, Hospital Geral, Centro Hospitalar e Universitário de Coimbra - Coimbra/PT

- ***Intrahepatic portacaval collaterals -*** These are spontaneous direct portacaval shunts, imitating in a natural way the available treatment options (surgical portosystemic shunts, TIPS). Another phenomenon is the finding of hepatofugal flow in the right portal vein branch but with a hepatopetal flow in the portal vein trunk. In this situation, the intrahepatic collaterals connect with the right portal branch, and the blood drains to the left portal vein, leaving the liver through a recanalized umbilical vein (Fig. 9 on page 23).

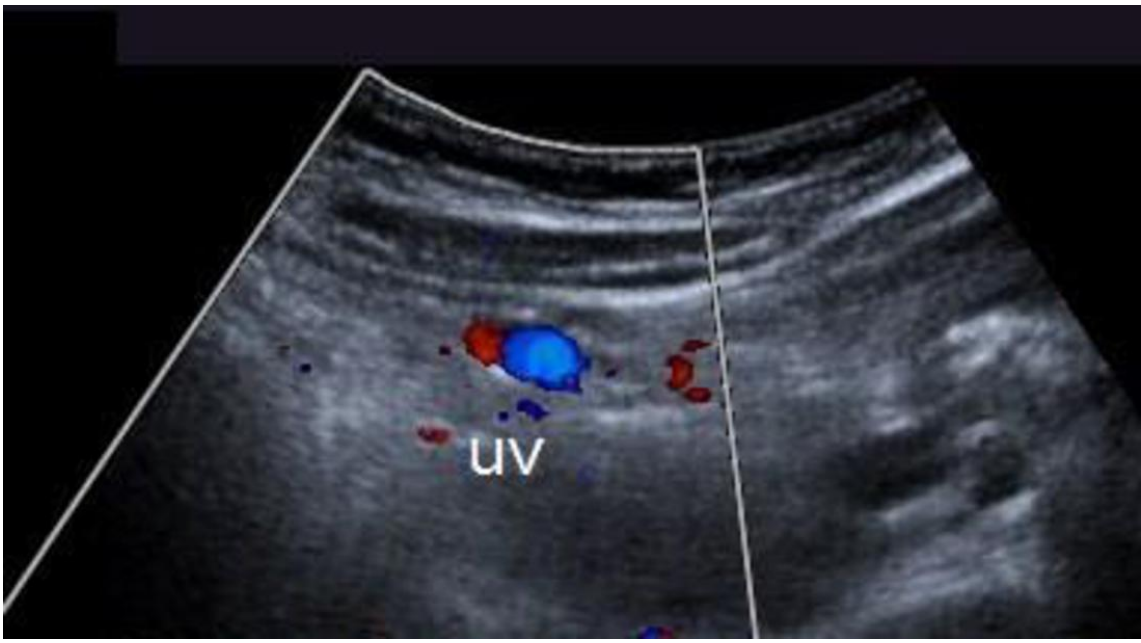

Fig. 9: Color Doppler showing a patent umbilical vein.
References: Radiologia, Hospital Geral, Centro Hospitalar e Universitário de Coimbra - Coimbra/PT

- ***Extrahepatic -*** Prominent collaterals, typically the ascending lumbar, azygos, and hemiazygos veins, may be seen in patients with Budd-Chiari Syndrome because of obstruction of the intrahepatic inferior vena cava.

Caudate Lobe

A caudate vein equal to or larger than 3 mm is a specific sign of Budd-Chiari Syndrome in the absence of heart failure. This sign is found in half of patients. This is the only segment that drains directly into the inferior vena cava and it has a special relevance in patients with Budd-Chiari Syndrome because in many cases the liver venous drainage is preserved through this pathway, leading to an enlargement of both the vein and the lobe (Fig. 10 on page 24). The enlarged caudate lobe may cause compression of the inferior vena cava. Enlargement of the normally small accessory hepatic veins may also occur.

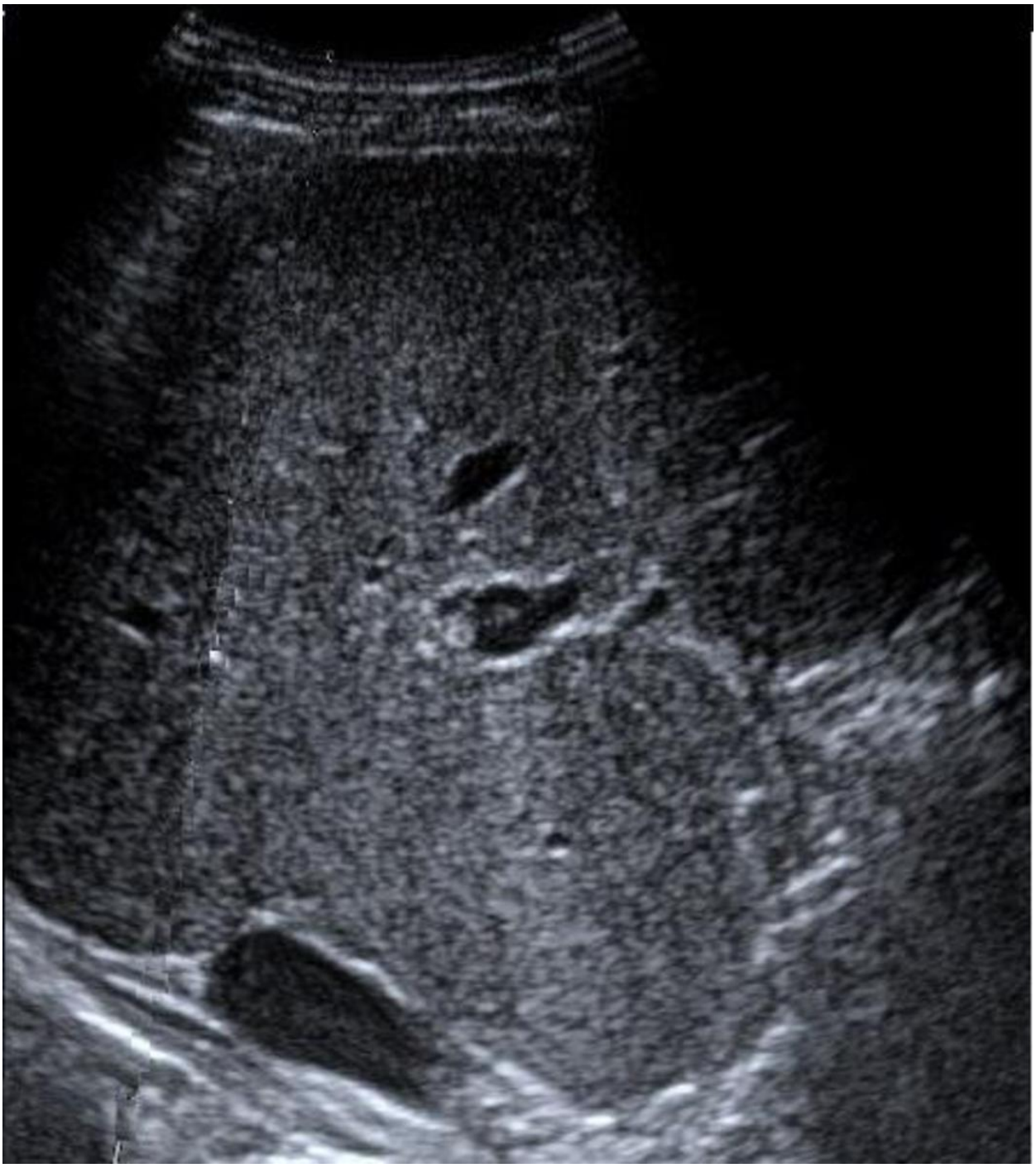

Fig. 10: Ultrasound image showing an enlarged caudate lobe, a sign seen in half of the patients with Budd-Chiari Syndrome.
References: Radiologia, Hospital Geral, Centro Hospitalar e Universitário de Coimbra - Coimbra/PT

Other Signs

Regardless of the cause, prolonged obstruction of venous outflow and decrease of portal venous flow leads to hepatic ischemia with subsequent elevation of hepatocellular growth factors. Multiple benign hepatic nodules (adenomatous hyperplastic nodules, nodular regenerative hyperplasia, and regenerative nodules) have been observed in pathologic studies in the majority of the patients. The routine use of imaging techniques in the follow-up of patients with Budd-Chiari Syndrome has resulted in increased lesion detection. These nodules share the feature of hypervascularity with hepatocellular carcinoma, so it is not possible to differentiate between them by using imaging techniques. Biopsy is advised in doubtful cases.

Nonspecific morphologic changes such as liver enlargement and hypoechogenicity of the segments drained by the obstructed hepatic vein or veins are observed in the acute phase. In the chronic stage, persistent hepatic outflow obstruction results in fibrosis, and the affected areas shrink and show parenchymal heterogeneity similar to that of liver cirrhosis.

Images for this section:

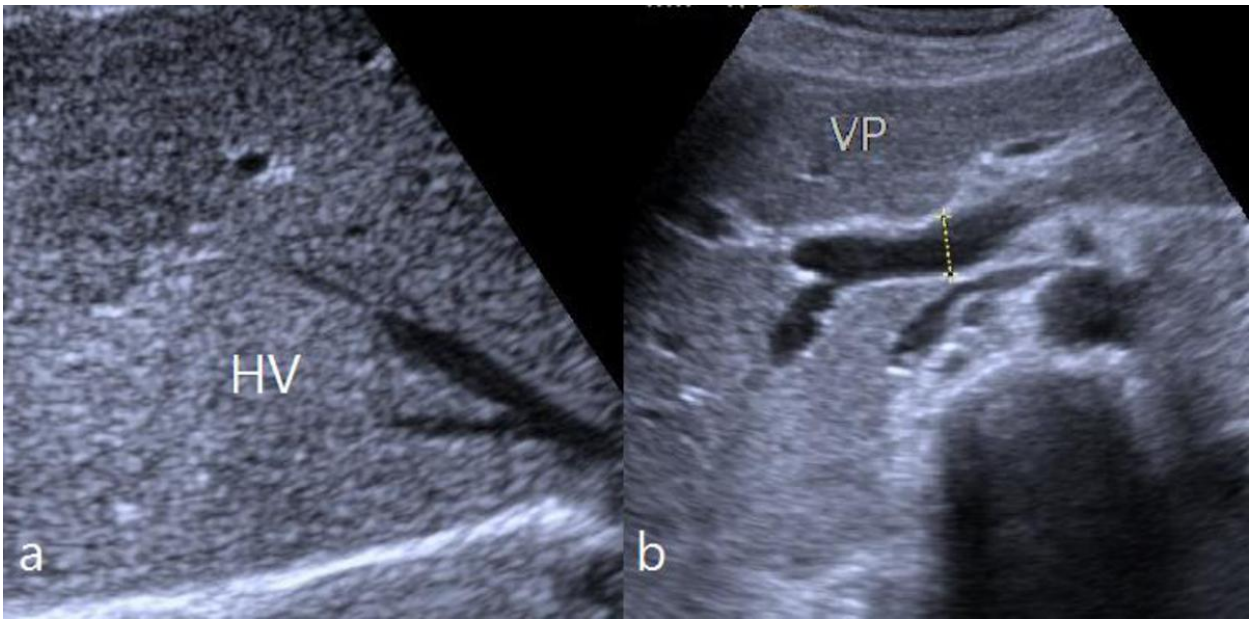

Fig. 3: Ultrasound images of normal hepatic veins (a) and portal vein (b) in gray scale (HV - hepatic veins; VP - portal vein).

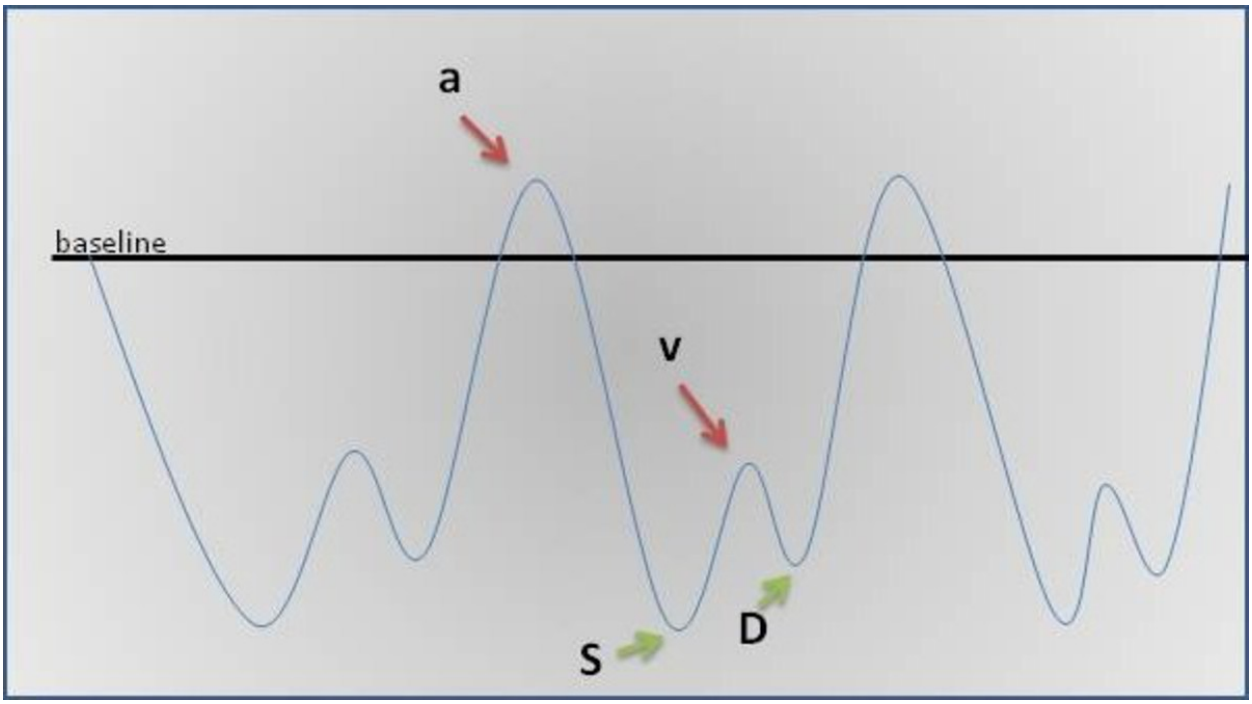

Fig. 4: Schematic figure showing the normal triphasic trace in Dopller evaluation of the hepatic veins.

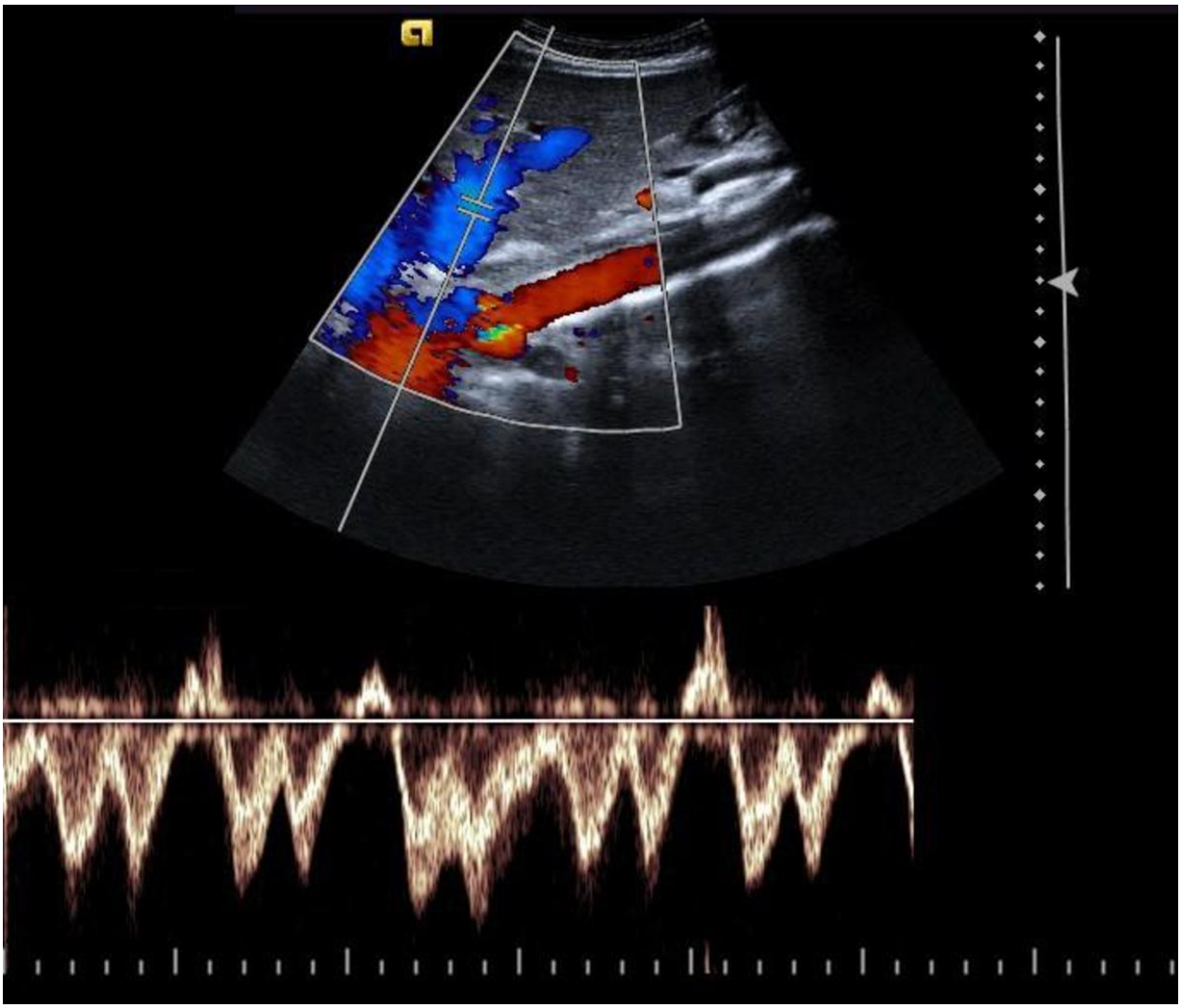

Fig. 5: Normal color and spectral evaluation of an hepatic vein.

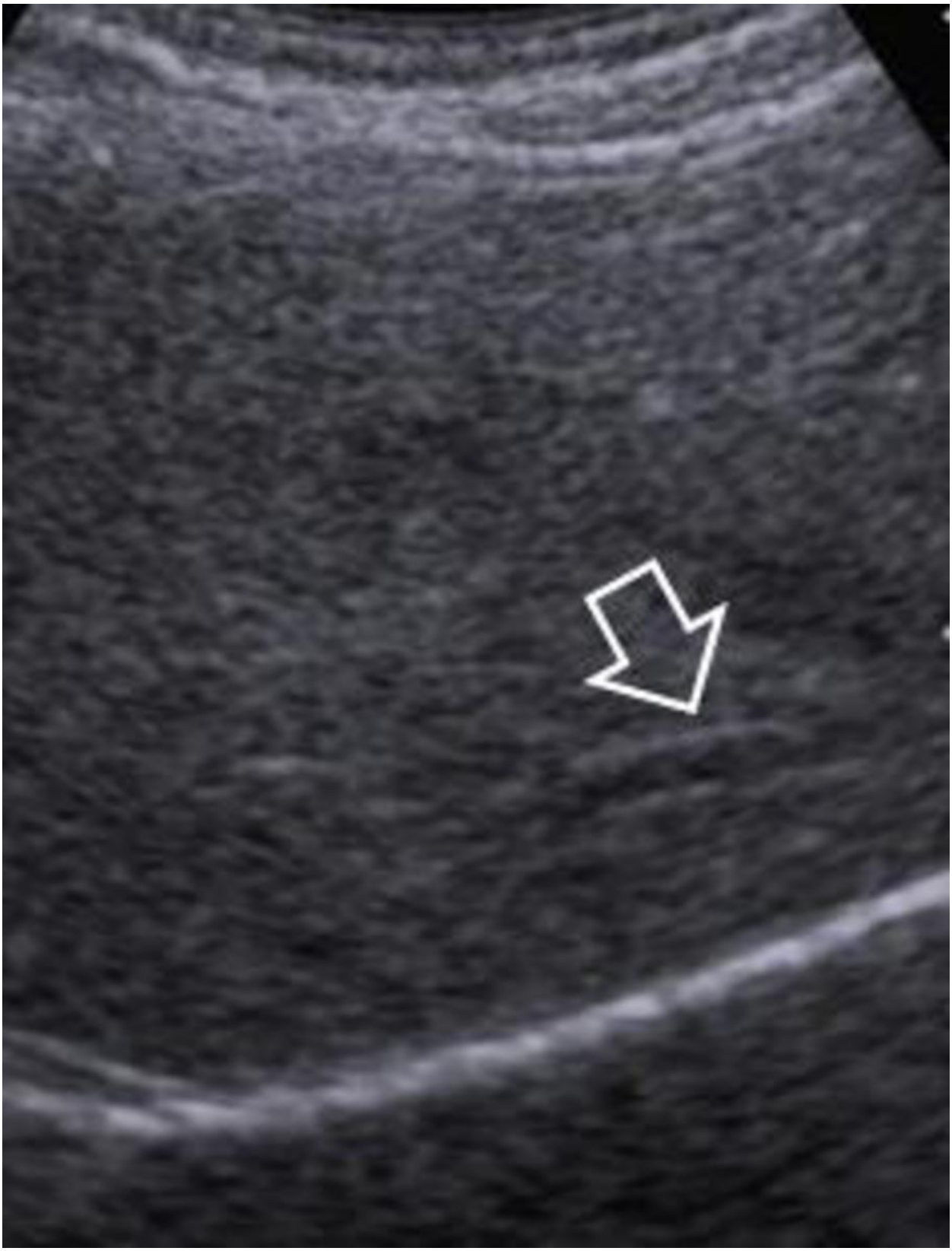

Fig. 7: Gray scale ultrasound showing echogenic material within the lumen of the hepatic vein (white arrow).

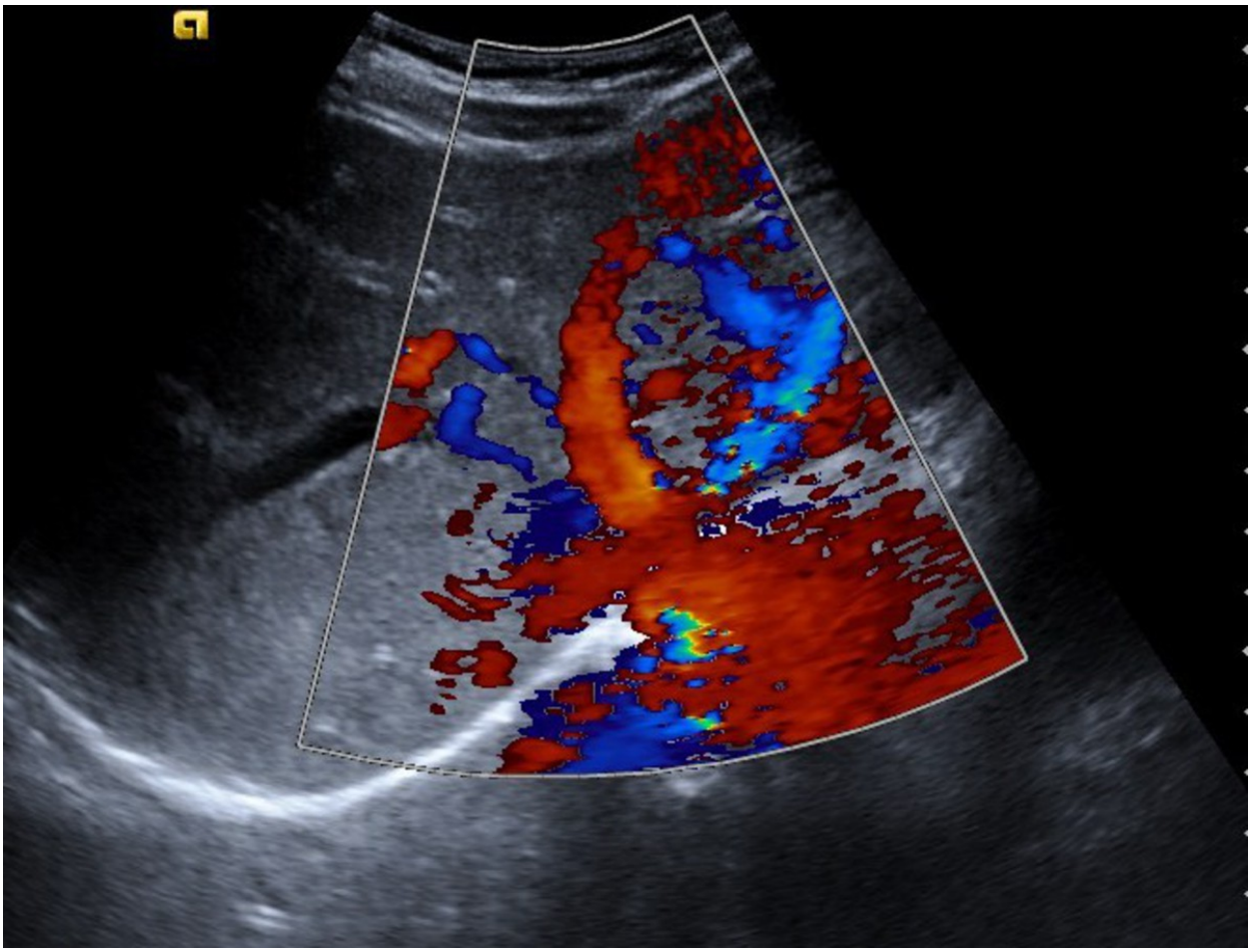

Fig. 8: Color Dopler ultrasound showing a pattern of bicolored hepatic veins (two adjoining hepatic veins with flow in opposite directions on color Doppler sonography).

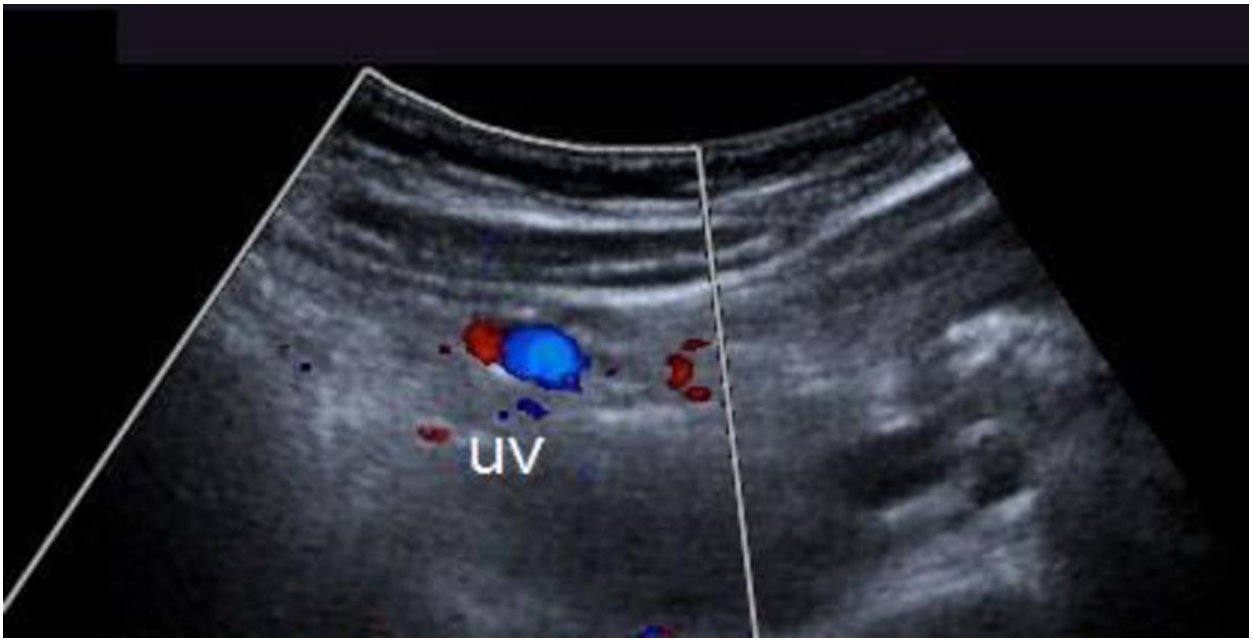

Fig. 9: Color Doppler showing a patent umbilical vein.

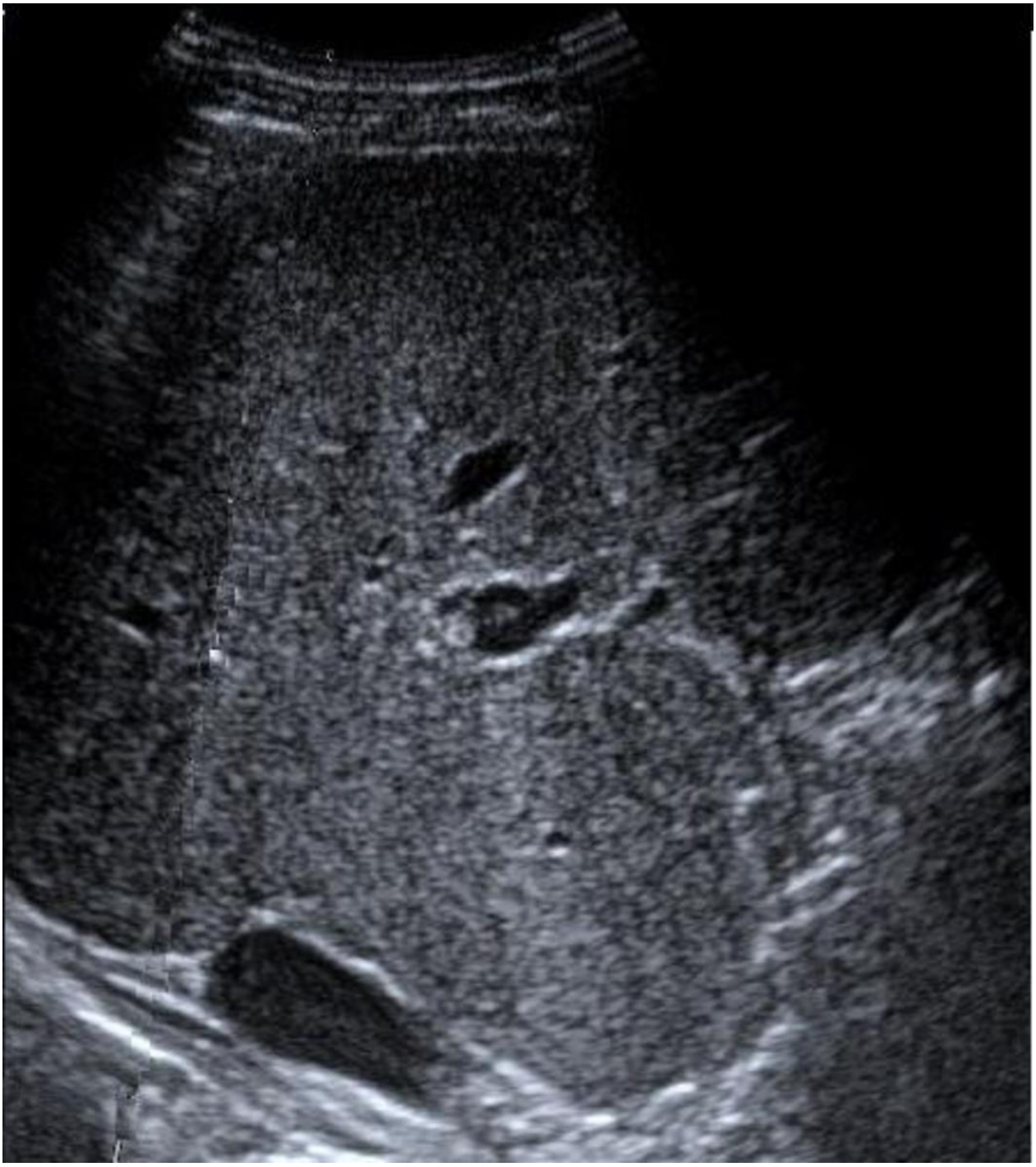

Fig. 10: Ultrasound image showing an enlarged caudate lobe, a sign seen in half of the patients with Budd-Chiari Syndrome.

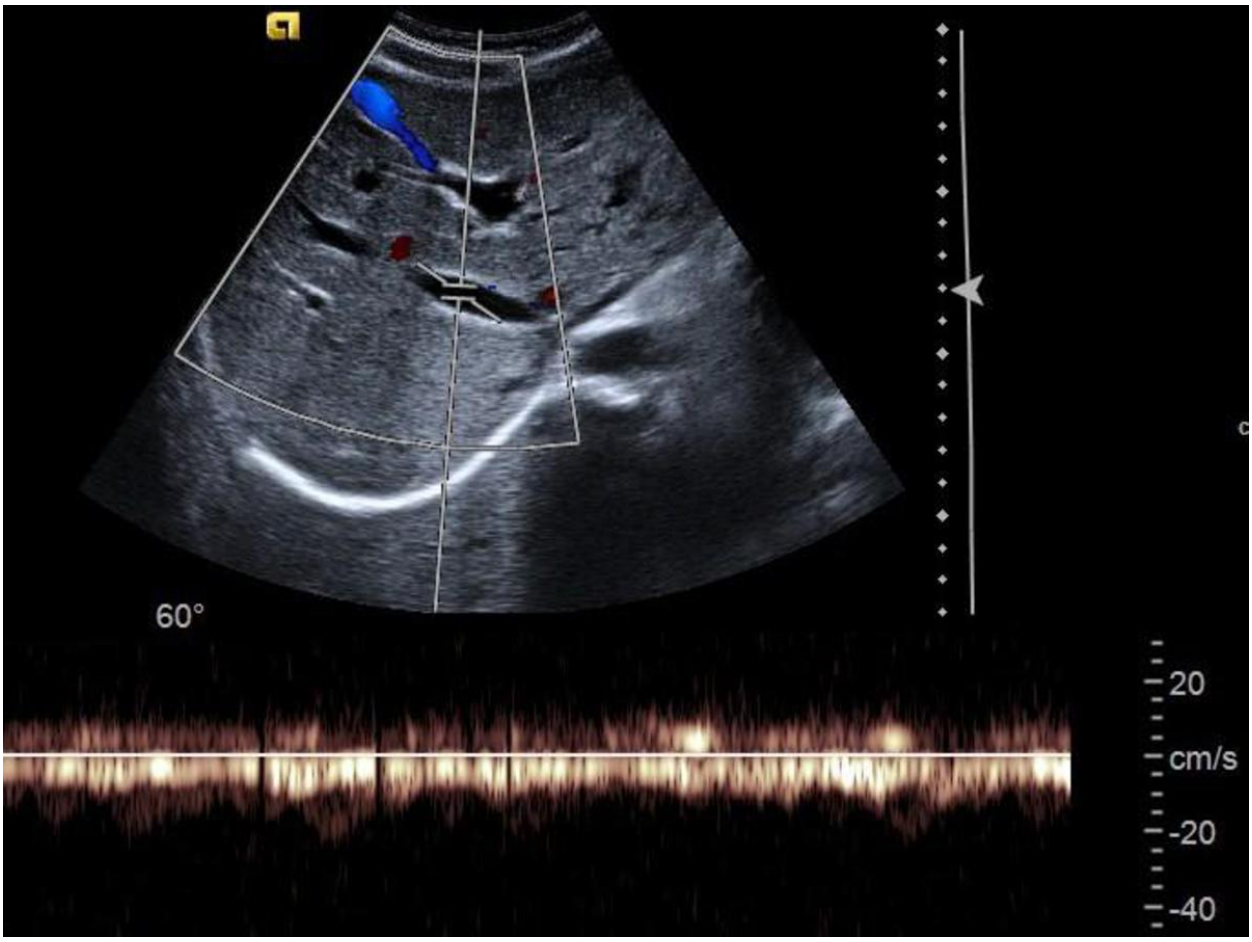

Fig. 6: Abnormal spectral Doppler of an hepatic vein - monophasic trace.

Conclusion

Liver Doppler ultrasound is a very useful primary diagnostic tool in Budd-Chiari Syndrome as it can identify direct and indirect signs of hepatic venous outflow obstruction and characterize it.

Personal information

email: kat.catarina@gmail.com

References

Bargalló X, Gilabert R, Nicolau C, García-Pagán JC, Ayuso R, Brú C. Sonography of Budd-Chiari Syndrome. AJR 2006; 187:W33-W42

Desser TS, Sze DY, Jeffrey RB. Imaging and Intervention in the Hepatic Veins. AJR 2003;180:1583-1591 0361-803X/03/1806-1583

Grant EG, Perrella R Tessler FN, Ronald JN. Budd-Chiari Syndrome: The Results of Duplex and Color Doppler Imaging. AJR152:377-381, February 1989

McNaughton DA, Abu-Yousef MM, Doppler US of the Liver Made Simple RadioGraphics 2011; 31:161-188